

# Deformities of cerebral palsy treated by ilizarov technique

## Abstract

Cerebral palsy is a condition that affects thousands of babies and children each year. It is not contagious, which means no one can catch it from anyone who has it. The word cerebral means having to do with the brain. The word palsy means a weakness or problem in the way a person moves or positions his or her body. A kid with Cerebral palsy (CP) has trouble controlling the muscles of the body (hall mark of the condition is motor dysfunction, i.e. there is abnormal muscle tone, abnormal posture and movement).<sup>1,2</sup> Normally, the brain tells the rest of the body exactly what to do and when to do it. But because CP affects the brain, depending on what part of the brain is affected, a kid might not be able to walk, talk, eat or play the way most kids do. It is a non-progressive but often changing motor impairment syndromes. It is usually secondary to an insult of limited duration or anomalies of the brain arising in the early stages of development. (Viz. prenatal, intranatal, neonatal and post natal up to 5 years). The changing clinical picture results from developmental maturation and intervention. The clinical expression of the case depends on the extent and area of brain damage, growth of the child, coexisting developmental problems.

Volume 4 Issue 1 - 2016

**Bari MM,<sup>1</sup> Shahidul Islam,<sup>2</sup> Shetu NH,<sup>2</sup> Mahfuzer Rahman<sup>2</sup>**<sup>1</sup>Chief Consultant, Bari-Ilizarov Orthopaedic Centre, Visiting and Honored Prof., Russian Ilizarov Scientific Centre, Russia<sup>2</sup>Bari-Ilizarov Orthopaedic Centre, Bangladesh**Correspondence:** Mofakhkharul Bari, Chief Consultant, Bari-Ilizarov Orthopaedic Centre, Visiting and Honored Professor, Russian Ilizarov Scientific Centre, Kurgan, Tel +88 01819 211595, Email bari.ilizarov31@gmail.com**Received:** December 16, 2015 | **Published:** January 04, 2016

## Introduction

Cerebral palsy is a condition that affects thousands of babies and children each year. It is not contagious, which means no one can catch it from anyone who has it.

The word cerebral means having to do with the brain. The word palsy means a weakness or problem in the way a person moves or positions his or her body. A kid with Cerebral palsy (CP) has trouble controlling the muscles of the body (hall mark of the condition is motor dysfunction, i.e. there is abnormal muscle tone, abnormal posture and movement).<sup>1,2</sup> Normally, the brain tells the rest of the body exactly what to do and when to do it. But because CP affects the brain, depending on what part of the brain is affected, a kid might not be able to walk, talk, eat or play the way most kids do.

It is a non-progressive but often changing motor impairment syndromes. It is usually secondary to an insult of limited duration or anomalies of the brain arising in the early stages of development. (Viz. prenatal, intranatal, neonatal and post natal up to 5 years). The changing clinical picture results from developmental maturation and intervention. The clinical expression of the case depends on the extent and area of brain damage, growth of the child, coexisting developmental problems.

## Sings and symptom

Symptoms of cerebral palsy can be as simple as having difficulty with fine motor tasks like writing or using scissors or as profound as being unable to maintain balance or walk. Severely affected patients may have involuntary movements, such as uncontrollable hand motions and drooling. Others suffer from associated medical disorders, such as seizures, speech problem, hearing problem, language disorder, ocular problem (i.e. strabismus, refractory errors, field's defects), feeding difficulties, behavioral problems and mental retardation.

## Types of cerebral palsy (CP)

Cerebral palsy can be classified as:

### I. Physiological

#### a. Spastic

#### b. Dyskinetic (dystonic and athetoid)

#### c. Hypotonic

#### d. Ataxic

#### e. Mixed

### II. Topographic

#### a. Quadri/tetraplegia

#### b. Hemiplegia

#### c. Diplegia

#### d. Monoplegia

#### e. Triplegia

## Spastic cerebral palsy (CP)

Spastic cerebral palsy (CP) is the most common type of cerebral palsy. It causes the muscles to be stiff and permanently contracted. Spastic cerebral palsy is often sub classified as one of five types that describe the affected limbs. The names of these type combine a Latin prefix describing the number of affected limbs (e.g. di-means two) with the term plegia or paresis, meaning paralyzed or weak.<sup>3,4</sup>

### I. Diplegia: either both arms or both legs

### II. Hemiplegia: limbs on only one side of the body

### III. Quadriplegia: all four limbs

### IV. Monoplegia: one limb (extremely rare)

### V. Triplegia: three limbs (extremely rare)

**Spastic diplegia:** Spastic diplegia affects the legs more than the arms. The legs often turn in and cross at the knees. This causes a scissors gait, in which the hips are flexed, the knees nearly touch, the feet are flexed and the ankles turn out from the leg, causing toe-walking. Learning disabilities and seizures are less common than in spastic hemiplegia.

**Spastic hemiplegia:** Persons with spastic hemiplegia (hemiparesis) also may experience hemiparetic tremors-uncontrollable shaking of the limbs on one side of the body. Severe hemiparetic tremors can

seriously impair movement. The arm is generally affected more than the leg. Learning disabilities, vision problems, seizures and dysfunction of the muscles of the mouth and tongue are classic symptoms.

**Spastic quadriplegia:** Spastic quadriplegia involves all four limbs. There is dysfunction of the muscles of the mouth and tongue, seizures, medical complication and increased risk for cognitive difficulties.

**Mixed CP:** Mixed CP involves two or more types of cerebral palsy. While any mix of types and subtypes can occur, the most common are athetoid-spastic-diplegic and athetoid-spastic-hemiplegic; the least common is athetoid-ataxic. It is possible to have a mix of all three (spastic-athetoid-ataxic).

### Complication

Some people with CP have associated disorders, such as impaired intellectual development, seizures, failure to grow and thrive and vision and sense of touch problems. Roughly a third of patients with CP also have mild intellectual impairment, another third are moderately or severely impaired and the remainder, intellectually normal. Mental impairment is most common in children with spastic quadriplegia.

### Diagnosis

The diagnosis of CP is essentially involves detail history of prenatal, natal and postal history and careful physical and neurodevelopment examination to identify deficit type and topography, which is required for management. Early identification has significant implication for the family and necessitates early intervention to achieve the maximum holistic potential of the child. The philosophy behind early intervention is based on the following facts:<sup>1,5,6</sup>

- I. A neurological insult recovers better with stimulation.
- II. I.Q. of emotionally deprived children is poorer than stimulated children.
- III. The plasticity of the brain in the first decade of life provides a window of opportunity for active intervention.
- IV. Actually a child with CP is not hopeless. Half of the child with CP have average or above I.Q.
- V. With timely help and proper guidance a vast majority can lead active, self supporting and long lives.
- VI. Thus early diagnosis is prerequisite.

### Evaluation

The diagnosis of CP is essentially clinical. It involves a detail prenatal, natal and post natal history and careful physical and neurodevelopmental examination to identify deficit type and topography which is required for management.

### Investigation

Laboratory test are not necessary to confirm diagnosis. Brain imaging studies including USG, CT and MRI may be useful in elucidating the etiology of CP and suggesting prognosis. Vision, auditory screening along with EEG should be done if patient is not improving after adequate physiotherapy.

### Materials and methods

Since 1990 to till 2014, we treated 46 patients of different categories of CP. Outcome of the patients are satisfactory (Figure 1 & 2).

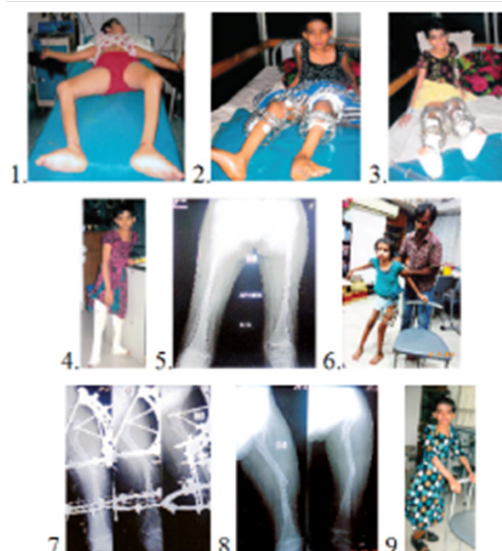
### Management

It is multidisciplinary approach.<sup>7-9</sup>

- I. Physical Therapy: Through this helps the child walking, sitting and keeping his/her balance. Also to prevent contracture.
- II. Occupational therapy: Help the child develop fine motor skills such as dressing, feeding, writing and other daily living skills.
- III. Speech therapy: To develop communication skill.
- IV. Feeding problem: Initially start with soft, small frequent feed. Drooling can be minimized by improving swallowing. Drugs are not very effective.
- V. Educational problem: Mild CP does well in mainstream schools. Moderate to severe CP need to be educated in special school.
- VI. Communication: Discourage sign language and encourage speaking.
- VII. Spasticity: If it does not improve with physiotherapy, then Botulinum Toxin Type-A injection can be given, which block release of acetylcholine from presynaptic terminal and blocks signal transmission at neuromuscular junction. It works for 3-5 months. Beclophen orally or intrathecal continuous pump can be implanted.

### Choice of surgery

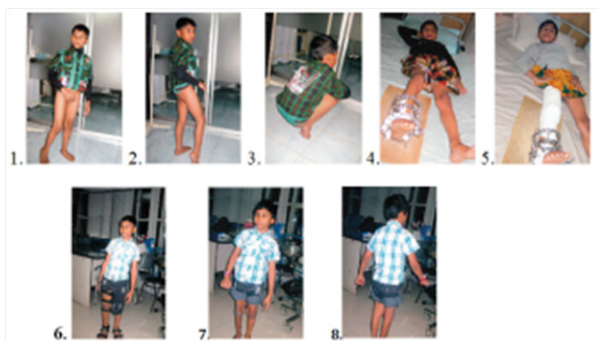- I. Operation on muscles and tendons
- II. Tenotomy, tendon lengthening tendon transfers
- III. Myotomy and muscle transposition
- IV. Operation on bones and joints
- V. Bone lengthening by Ilizarov technique
- VI. Osteotomies to correct knock knee
- VII. Arthrodesis of wrist, hip and foot to correct deformity



**Figure 1**

- I. 12 years old girl with bilateral knee flexion contracture with bilateral pes plano valgus.

2. Correction of both knee flexion contracture with Ilizarov apparatus.
3. Grice operation was done in both ankle (Extra articular arthrodesis).
4. Patient is walking with plaster cast. Since birth she did not stand and walk.
5. Congenital left hip dislocation.
6. Ilizarov in the left hip and thigh.
7. X-ray of PSO (Pelvic Support Osteotomy).
8. After removal of Ilizarov apparatus
9. Patient is walking with KAFO.



**Figure 2**

1. 9 years old boy – Right Pes Equinus >650
2. Right Pes Equinus >650 (Lateral view).
3. Cannot squat.
4. During treatment with Ilizarov.
5. Plaster immobilization in the knee with Ilizarov in the ankle.
6. With KAFO (knee ankle and foot orthosis).
7. Clinical appearance of the patient. Final follow up (Front view)
8. Clinical appearance of the patient. Final follow up (Back view).

### Aim of Surgery in CP

- I. To correct the deformity
- II. To balance the muscle power
- III. To stabilize uncontrollable joints

### Complication

So early intervention is the key for improvement of CP, specially the first 2 years is most important. This is the time when brain is growing very fast. In simple word this is the express train. Try to catch it. If you miss it try to catch the local train, which is up to 5 years. Still it is better than something.

### Acknowledgments

None.

### Conflicts of interest

None.

### References

1. Root L. Treatment of hip problems in cerebral palsy. *Instr Course Lect.* 1987;36:237–252.
2. Lonstein JE, Beck K. Hip dislocation and subluxation in cerebral palsy. *J Pediatr Orthop.* 1986;6(5):521–526.
3. Bleck EE. The hip in cerebral palsy. *Orthop Clin North Am.* 1980;11(1):79–104.
4. Wood E, Rosenbaum P. The gross motor function classification system for cerebral palsy: a study of reliability and stability over time. *Dev Med Child Neurol.* 2000;42(5):292–296.
5. Robin J, Graham HK, Baker R, et al. A classification system for hip disease in cerebral palsy. *Dev Med Child Neurol.* 2009;51(3):183–192.
6. Jones DH. Shenton's line. *J bone Joint Surg [Br].* 2010;92(9):1312–1315.
7. Persson-Bunke M, Hagglund G, Lauge-Pedersen H. Windswept hip deformity in children with cerebral palsy. *J Pediatr Orthop B.* 2006;15(5):335–338.
8. Carr C, Gage JR. The fate of the nonoperated hip in cerebral palsy. *J Pediatr Orthop.* 1987;7(3):262–267.
9. Bari MM. *A color atlas of limb lengthening*, surgical reconstruction and deformity correction by Ilizarov technique. 2013;pp.212–228.