

# Treatment of Cubitus Varus with open Medial Wedge Osteotomy using Ilizarov Technique

## Abstract

### Aim of study

Cubitus varus is the most common angular deformity that results from supracondylar fracture in children there are different surgical techniques of treatment but the Ilizarov technique offers superior advantages. The aim and goal of our study is to assess the result of post traumatic cubitus varus treated with Ilizarov technique. Between January 2000 and January 2013, 18 patients were treated with Ilizarov technique. A varus angle of more than 10 degrees and varus deformity secondary to supracondylar fractures that had been previously treated by closed manipulation and other operative methods were the inclusion criteria. The varus was measured on the radiograph using the humerus ulnar mid diaphyseal line. The CORA (Centre of rotation of angulation) was above the olecranon fossa, the osteotomy was performed at CORA and hinge was also placed at CORA. If the CORA is at the olecranon fossa and below, the hinge is placed at the CORA but the osteotomy is performed 1 cm above the olecranon process. The hinges are placed in the sagittal plane anteriorly and posteriorly in Ilizarov frame made up of two rings. The average duration of Ilizarov fixator was 12.5 weeks while the duration of follow up averaged 30 months. The average injury duration at presentation was 4 years. The results were graded as excellent, good and poor based on the protocol from Bellemore et al.<sup>1</sup> Ilizarov technique provides gradual, controlled, coordinated accurate correction of cubitus varus without any open surgery with the advantage of full correction post operatively.

**Keywords:** cubitus varus, ilizarov, deformity, supracondylar fracture

Volume 2 Issue 5 - 2015

Bari MM,<sup>1</sup> Shahidul Islam,<sup>2</sup> NH Shetu,<sup>2</sup> Mahfuzer Rahman,<sup>2</sup> Mashiur H Munshi,<sup>3</sup> Md Golam Mostofa,<sup>2</sup> Naima Ferdousi<sup>3</sup>

<sup>1</sup>Bari -Ilizarov Orthopedic Centre, Visiting and Honored Prof. Russian Ilizarov Scientific Centre, Bangladesh

<sup>2</sup>Bari-Ilizarov Orthopaedic Centre, Bangladesh

<sup>3</sup>National Institute of Traumatology and Orthopaedic Rehabilitation, Bangladesh

**Correspondence:** Mofakkhkarul Bari, Bari-Ilizarov Orthopaedic Centre, 72, Satmasjid Road, Nizams Shankar Plaza, Dhanmondi, Dhaka, Bangladesh, Tel +8801819211595, Email bari.ilizarov31@gmail.com

**Received:** April 06, 2015 | **Published:** May 7, 2015

## Introduction

Cubitus varus is a late sequelae of poorly treated or those in which reduction was lost without follow up. The reason is the medical displacement and rotation of the distal fragment. Dr. Smith showed in his experimental studies that varus tilting of the distal fragment was the most important cause of the change in the carrying angle and showed that rotation of distal fragment was most important situation leading to this.<sup>2</sup> La Belle et al.<sup>3</sup> found varus tilting of the distal fragment in all their patients with cubitus varus after supracondylar fractures. Several techniques have been mentioned in the literature for cubitus varus deformity correction. King & Secor<sup>4</sup> mentioned an opening medial wedge osteotomy, Amspacher & Messenbaugh<sup>5</sup> reported good results with oblique osteotomy combined with de rotation. But most surgeons preferred lateral closing wedge osteotomy. The fixation ranged from plate fixation, Kirchner wire fixation, screw fixation.

De Rossa & Grazious<sup>6</sup> described step cut osteotomy fixed with single cortical screw. Many orthopaedic surgeons used external fixation that range from simple uni planar fixators to Ilizarov ring fixators.<sup>7-9</sup>

## Materials and methods

18 patients at NITOR (National Institute of Traumatology and Orthopaedic Rehabilitation), Mymensingh Medical College, Bari-Ilizarov Orthopaedic Centre, Dhaka from 2000 to 2013 who had cubitus varus were included in this study. A varus angle of 10 degrees and deformity secondary to supracondylar fractures that had been previously treated by closed manipulation and other operative methods were the inclusion criteria. The varus was measured on the x-ray using

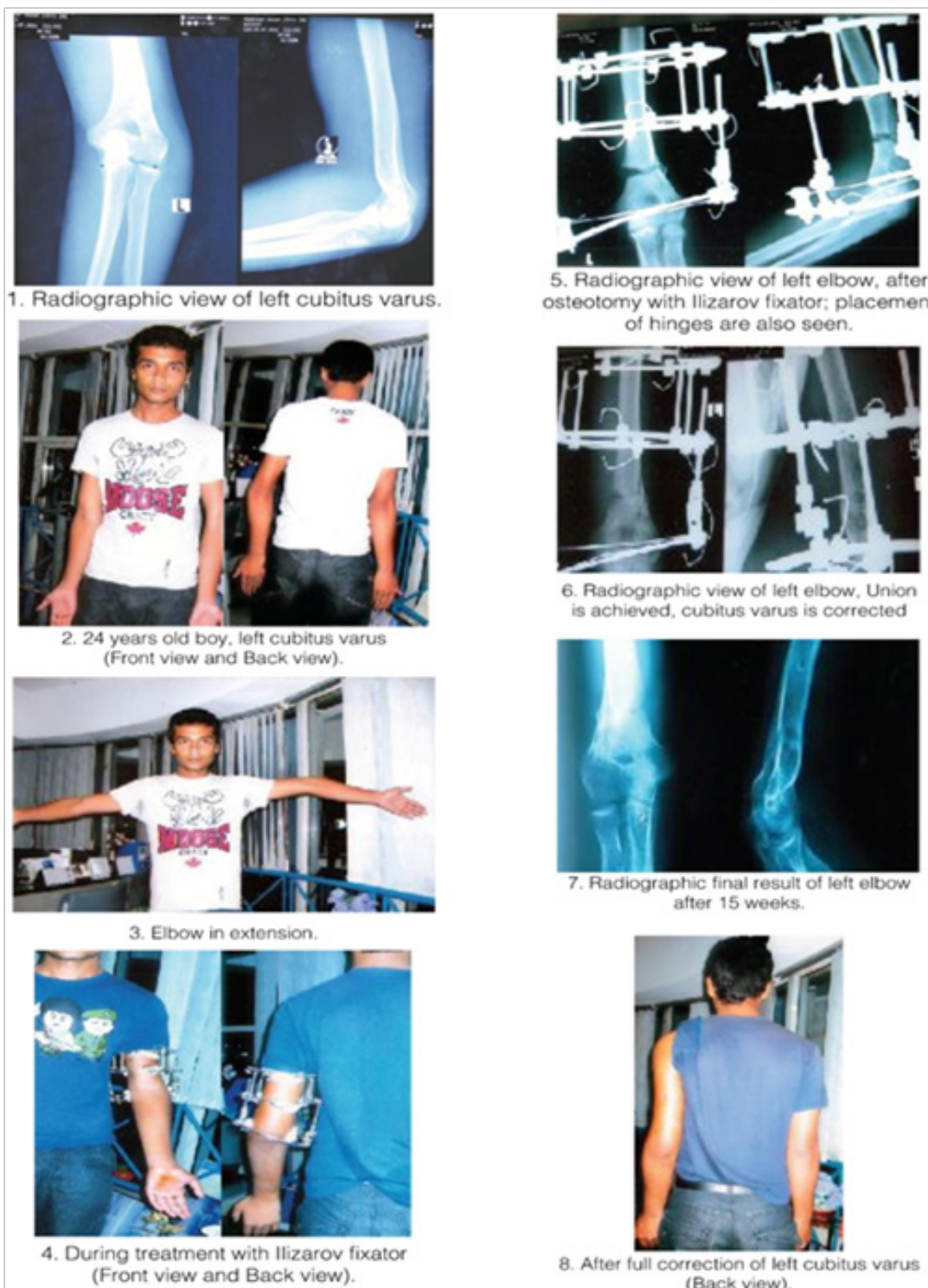
the humero-ulnar mid diaphyseal line. The point where these two lines meet is called CORA.<sup>10</sup> (Centre of rotation of angulation). If the CORA is above the olecranon fossa then osteotomy was performed at this level and hinge was placed at this level in the frame. If CORA is at the olecranon fossa and below, the hinge is placed at the CORA but the osteotomy is performed 1 cm above the olecranon which is confirmed with image intensifier. The only Snag here is that there will be some translation of the bone fragments that had no cosmetic significance as bone remodels with time. The hinges are placed in the sagittal plane anteriorly and posteriorly in the Ilizarov frame consists of two rings. At first, a distal wire is inserted from the postero-lateral aspect of the lateral condyle towards anterior surface of the medial condyle, at 6° to 8° valgus inclination to the joint line. Wire is fixed to the distal ring.

Distal ring is fixed with a second wire inserted from the medial epicondyle to the anterior cortex of the lateral condyle. Another drop wire is inserted at the posterolateral aspect of the lateral condyle to strengthen the fixation. In the proximal ring, another wire is fixed anterolaterally to complete the fixation the wires are fixed to the rings and tensioned properly. The rings were connected to three threaded rods equidistant from each other. The osteotomy was performed about 1 cm above the Olecranon fossa from medial side under image intensifier guidance. Acute correction of the deformity was done using the hinge as axis of rotation. The rods were then tightened on to the two rings. Any residual deformity was corrected post operatively starting from day 4 or 5. The patients were advised to do exercise at the elbow and shoulder from day 1 actively and passively.

The results were graded as excellent, good or poor according to Bellemore et al.<sup>1</sup> An excellent means, the loss of carrying angle was

<5° or less and the loss of flexion or extension 10 degrees or less. A good means, loss of carrying angle of between 6-10 degrees and loss of flexion or extension of 20 degrees or less. A poor means, the loss

of carrying angle over 10 degrees or limitation of range of flexion or extension more than 20 degrees (Figures 1-8) Corresponds to case 1 given in the Table 1.



## Results

18 patients were treated this Ilizarov technique during the period of 2000 to 2013. The mean duration of Ilizarov frame was 12, 5 weeks and mean duration of follow up was 30 months. The average

injury duration at presentation was 4 years. The details of the patients are given in the Table 1. All patients had excellent results. Wire inflammation was in 5 cases. These were minor and were treated by local wound dressings and oral antibiotics. No re-fracture was observed after removal of the Ilizarov apparatus.

**Table I** Showing results of case

Case	Age of the Patients (yrs.)	Sex	Varus (angle)	Side	Union Time (weeks)	Follow up Months	Complication Results	
01	24	M	30°	L	15	36	Pin site	Excellent
02	19	M	28,5	L	12	36	inflammation	Excellent
03	15	M	20,0	L	12	30		Excellent
04	14	F	11,3	R	13	32	5	Excellent
05	17	M	14,5	R	14	50		Excellent
06	13	F	12,5	L	12	40		Excellent
07	12	F	13,3	R	12	40		Excellent
08	14	M	23,0	R	13	35		Excellent
09	17	F	20,2	R	14	26		Excellent
10	15	F	17,2	L	14	20		Excellent
11	12	M	18,3	L	12	25		Excellent
12	06	F	16,3	R	08	25		Excellent
13	09	M	15,0	R	10	20		Excellent
14	08	F	15,1	L	10	20		Excellent
15	21/2	F	12,2	R	08	18		Excellent
16	03	M	15,0	R	08	20		Excellent
17	07	M	14,3	L	08	35		Excellent
18	11	M	17,2	R	10	36		Excellent

## Discussion

Different authors have reported well to excellent results in treating cubitus varus using different surgical techniques.<sup>1,4,5,7-9,11</sup> The use of Ilizarov technique has been reported to have superior advantage over previously reported surgical interventions.<sup>11,12</sup> The Ilizarov technique is so versatile that it can correct multi plane deformity without any open intervention. The osteotomy is carried out through a small incision of 1 cm. In our series most of the cases were corrected acutely and immediately. Post-operative adjustment was done as need arises. Roach & Hernandez<sup>13</sup> reported that 2 of their 10 cases had poor results due to inadequate intraoperative correction. This was not so with Ilizarov device as one still have opportunity for correction of residual deformity post-operatively. Up to 35% poor results had been reported as due to loss of inadequate correction. 2 of 24 cases of Ippolito et al.<sup>14</sup> and 3 of 15 cases described by both King & Secor<sup>4</sup> and 5 of 45 cases treated by Oppenheim et al.<sup>15</sup> had nerve palsies. In our series no nerve palsies were recorded. Post-operative immobilization was necessary in patients whose bone fragments were fixed internally. It leads to elbow stiffness. This is not a problem in the patients with Ilizarov device because of exercise of the elbow and shoulder post operatively. Unsightly post-operative scars are seen in some studies.<sup>16,17</sup> The Ilizarov techniques avoid this problem requiring no incision for the passage of the wires.

## Conclusion

Our series shows to versatility, flexibility and controllability of Ilizarov technique in the treatment of cubitus varus. Ilizarov technique

provides accurate correction of cubitus varus deformity without any open surgery with advantage of correction postoperatively.

## References

1. Bellemore MC, Barrett IR, Middleton RW, et al. Supracondylar osteotomy of the humerus with correction of cubitus varus. *J Bone Joint Surg Br.* 1984;66(4):566-572.
2. Smith L. Deformity following supracondylar fractures of the humerus. *J Bone Joint Surg Am.* 1960;42(2):235-252.
3. Labelle H, Bunnell WP, Duhaime M, et al. Cubitus varus deformity following supracondylar fractures of the humerus in children. *J Pediatr Ortho.* 1982;2(5):539-546.
4. King D, Secor C. Bow elbow (cubitus varus). *J Bone Joint Surg Am.* 1951;33(3):572.
5. Amspacher JC, Messenbaugh JP. Supracondylar osteotomy of the humerus for correction of rotation and angular deformity of the elbow. *South Med J.* 1964;57:160.
6. DeRossa GP, Graziano GP. A new osteotomy for cubitus varus. *Clin Ortho.* 1988;236:160.
7. Koch PP, Exner Gu. Supracondylar medial wedge osteotomy with external fixation for cubitus varus deformity. *J Pediatr Orthop B.* 2003;21(2):116-122.
8. Song HR, Cho SM, Seoug ST, et al. Supracondylar osteotomy with Ilizarov fixation for elbow deformity in adults. *J Bone Joint Surg Br.* 1997;19(B):748-752.

9. Sangwan MM, Marya KM, Siwach RC, et al. Cubitus varus correction by distraction osteogenesis. *Indian J Med Sci.* 2002;56(4):165–171.
10. Bari MM. A color atlas of limb lengthening, surgical reconstruction and deformity correction by Ilizarov technique. 2013;pp. 336–339.
11. Karatosun V, Alekberov E, Alici C, et al. Treatment of cubitus varus using the Ilizarov technique of distraction osteogenesis. *J Bone Joint Surg Br.* 2000;82(7):1030–1033.
12. Piskin A, Tomak Y, Sen C, et al. The management of cubitus varus and valgus using the Ilizarov method. *J Bone Joint Surg Br.* 2007;89(12):1615–1619.
13. Hernandez MA, Roach JW. Corrective osteotomy for cubitus deformity. *J Padiatr Orthop.* 1982;14(4):487–491.
14. Ippolito E, Moneta IR, D' Arrigo C. Post traumatic cubitus varus; long term follow up of corrective supracondylar humeral osteotomy in children. *J Bone Joint Surg Am.* 1990;72(5):757–765.
15. Oppenheim WL, Clader TJ, Smith C, et al. Supracondylar humeral osteotomy for traumatic childhood varus deformity. *Clin Ortho.* 1984;188:34–39.
16. Barrett-IR, Bellemore MC, Kwon YM. Cosmetic results of supracondylar osteotomy for correction of cubitus varus. *J Padiatr Orthop.* 1998;18(4):445–447.
17. Hasler CC. Correction of Malunion after pediatric supracondylar elbow fractures. *Eur J Trauma.* 2003;29:309–315.