

# Treatment of neglected elbow dislocation using ilizarov ring fixator

## Abstract

We treated 14 neglected elbow dislocations with a mean age of 45 (15-50) years after arthrolysis which can be done by lateral, medial or combined lateral and medial approach with Ilizarov hinge external apparatus, from January 2000 to January 2014. The most preferred incision is combined lateral and medial because the joint is approached on all sides. In mild cases only lateral approach may be enough. The key to successful outcome for an open capsular release involves adequate surgical exposure. Out of 14 patients 12 were male and 2 female. The Ilizarov apparatus and Hinge technique represents a useful method for the successful treatment of neglected elbow dislocation.

**Keywords:** Neglected elbow dislocation, Ilizarov approach

Volume 3 Issue 5 - 2015

**Bari MM,<sup>1</sup> Shahidul Islam,<sup>2</sup> Shetu NH,<sup>2</sup> Mahfuzer Rahman<sup>2</sup>**

<sup>1</sup>Chief Consultant, Bari-Ilizarov Orthopaedic Centre, Visiting and Honored Prof., Russian Ilizarov Scientific Centre, Russia  
<sup>2</sup>Bari-Ilizarov Orthopaedic Centre, Bangladesh

**Correspondence:** Mofakhkharul Bari, Chief Consultant, Bari-Ilizarov Orthopaedic Centre, Visiting and Honored Professor, Russian Ilizarov Scientific Centre, Kurgan, Tel +88 01819 211595, Email bari.ilizarov31@gmail.com

**Received:** October 22, 2015 | **Published:** November 19, 2015

## Introduction

Neglected elbow dislocation is not an uncommon condition. It disturbs activities of daily living, such as reaching hand to face, toilet etc. It becomes a disability if both elbows are affected.

### Elbow range of movement

- Normal- 0 to 145°
- Functional- 30° to 130°, according to Morrey.<sup>1,4</sup>
- Good functional- 70° to 120°
- Functional pronation and supination are 50° each.

The aim of treatment of a neglected elbow dislocation is to achieve the functional range.<sup>1,4,5</sup> Causes of stiff elbow are varied. Post-traumatic or post-surgical stiff elbow is the commonest Table 1.

**Table 1** Causes of Stiff elbow

Post-Trauma - Neglected Elbow Dislocation	
Post-Surgery	
Heterotopic Ossification	
	Arthrogyposis
	Pterygium
Congenital	Club Hand
	Short Biceps
	Tuberculosis
Arthritis	Rheumatoid Arthritis
	Pyogenic
	Other Causes of Arthritis
Burns	
Paralytic	Cerebral Palsy
	Arthrogyposis
Prolonged Immobilization	

Hasting and Graham proposed a classification for heterotopic ossification of the elbow. Type-I heterotopic ossification involves no functional deficits, type-II results in some functional deficits and type III results in elbow ankylosis.<sup>6</sup>

## Materials and methods

For the last 14 years (2000-2014) 14 cases of neglected elbow dislocation were operated by medial or lateral approach or combined with the help of Ilizarov hinged distraction. The follow up period was (1-13) year's male predominated with an average age 45 years as demonstrated in Table 2.

**Table 2** Cases of neglected elbow dislocation were operated by medial or lateral approach or combined with the help of ilizarov hinged distraction

Sex	Qty.	Percentage
Male	12	85%
Female	2	15%

## Surgical management

Arthrolysis can be done by lateral, medial or combined (lateral & medial). Most preferred incision is combined (lateral & medial) as it allows joint approach on all sides. Key to successful outcome - adequate surgical exposure (Figure 1 & 2).

## Technique

- I. Lateral incision - 6cm proximal to the lateral epicondyle running posteriorly downwards over the epicondyle at upper 3rd of the extensor surface of forearm.
- II. Cleavage between anconeus and extensors is deepened, following detachment of common extensors at origin and then retracted.
- III. Brachialis is elevated from the lower 3rd of the humerus
- IV. Anterior capsule is cut from the coronoid process of ulna.
- V. One should be very careful with the ulnar nerve.
- VI. All myositic mass, scar tissue & fibrous tissue is removed.
- VII. If Elbow instability is identified - Ilizarov fixator or postoperative protection in a hinged orthosis may be needed.
- VIII. Medial incision - about 5cm, extending proximally and distal to the medial epicondyle.
- IX. The ulnar nerve is carefully retracted.

- X. Medial flexor origin is detached from bone following cutting of medial portion of the capsule - making the elbow free from all sides (gives a fair range of up to 10-20° of full extension).
- XI. In acutely flexed elbows, the brachialis may have to be detached from the coronoid, to avoid neuropraxia and vascular compromise.
- XII. If reduction is complete then the elbow is kept in flexion.
- XIII. Flexion of 120° is acceptable on the table. Sometimes head of the radius or tip of the olecranon process may have to be excised for increasing excursion.
- XIV. In old unreduced dislocations the limb is immobilized in 90° flexion to prevent redislocation.

**Rationale of distraction of the joint (Arthrodiastasis) by Ilizarov fixator: Achievements of distraction of the joints**

- It elongates the contracted ligaments and the soft tissue around the joint and thus further improves the mobility of the joint.
- Articular cartilage of the joint are separated, which prevents the cartilage.
- It stabilizes the elbow and allows early mobilization from day 1.

**If plastered** - elbow immobilized for at least 3 weeks.<sup>2,3,7</sup>

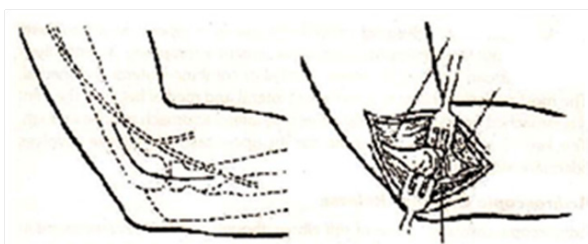
In majority of cases we applied hinged Ilizarov external fixator to achieve better results and better mobility.

**Ilizarov** - gives better result and better mobility - comparatively less costly and is very helpful.

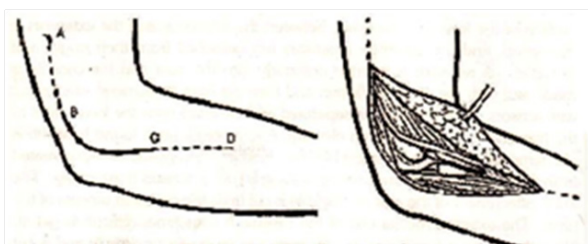
Other various types of hinged external fixators are

- I. Volkov- Oganesyanyan apparatus
- II. Mayo distraction device
- III. Compass universal hinged
- IV. Orthofix device

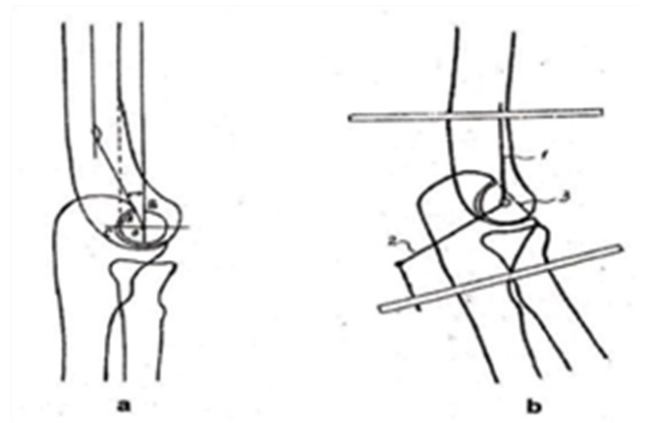
Diagrams of the elbow: a- angular and axial characteristics of the elbow, b- positioning of the hinge units of the fixator (1, 2- distraction rods of the hinge units, 3- the line, drawn through the tops of olecranon) (Figure 3).



**Figure 1** Lateral incision for elbow joint arthrolysis.



**Figure 2** Medial incision for elbow arthrolysis.

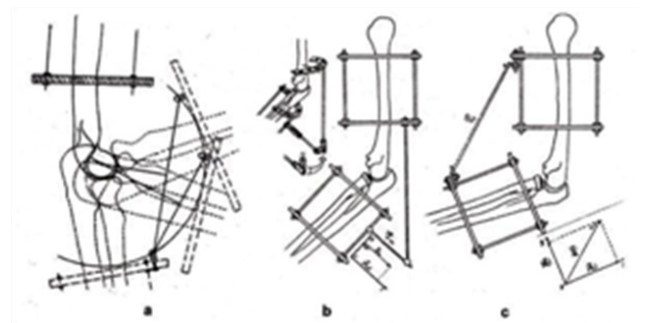


**Figure 3** Skiagrams of the elbow.

- a. Angular and axial characteristics of the elbow.
- b. Positioning of the hinge units of the fixator (1, 2- distraction rods of the hinge units, 3- the line, drawn through the tops of olecranon).

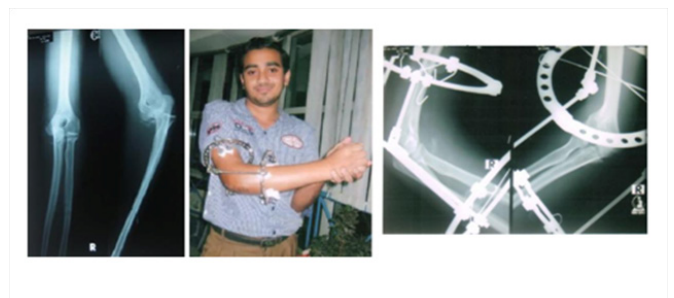
Diagram of the elbow and the Ilizarov fixator: a-determination of the elbow axis of rotation, b- vector resolution of forces for extension in the elbow using the force element, c- vector resolution of forces for flexion in the elbow using the force flexion element (Figure 4).

**Case Illustrations** (Figure 5-8)



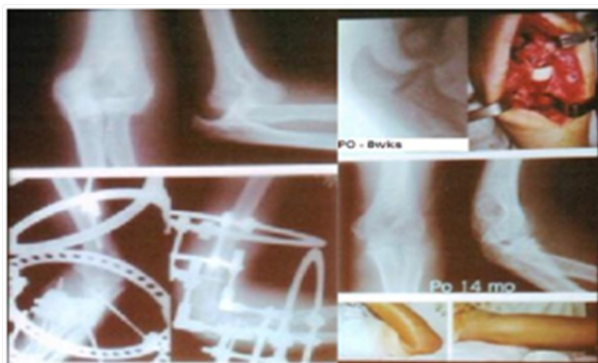**Figure 4** Diagram of the elbow and the Ilizarov fixator.

- a. Determination of the elbow axis of rotation.
- b. Vector resolution of forces for extension in the elbow using the force element.
- c. Vector resolution of forces for flexion in the elbow using the force flexion element.

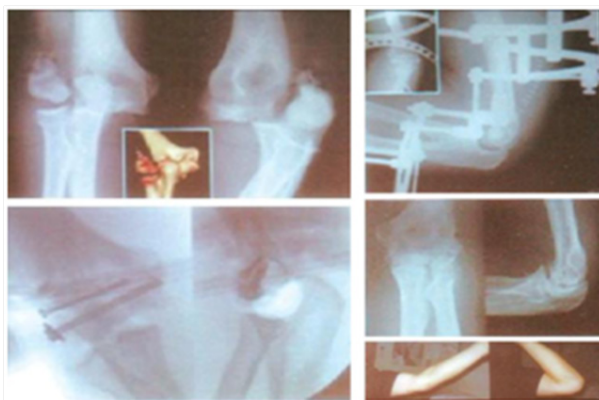

**Figure 5** Case I


- a. 3 months old dislocated rt. elbow of a 27 yrs. old man
- b. After reduction with Ilizarov. Gradual passive range of movement using hinge rod in stiffness.



**Figure 6** Case II 37 yrs. old male (neglected dislocated elbow) before and after treatment.



**Figure 7** Case III Old fracture dislocation (40 yrs.) PO- 20 months.



**Figure 8** Case IV

- X-ray of floating elbow G IIIB
- Floating elbow
- Fixation with Ilizarov apparatus
- Clinical appearance of the patient after treatment
- Patient could reach his hand for perineal hygiene.

## Complications

Complications are a fact of life that every surgeon has to face. In our series we managed all the complications by local care and applying antibiotics.

- Local skin complications
- Deep infections
- Pin tract infections
- Neurologic injuries
- Recurrence of the contracture
- Heterotopic ossification
- Ligament instability

## Results

Elbow contracture release, regardless of the surgical approach, has been highly successful, with an overall improvement in motion ranging from 29° to 65°. Most patients achieve a functional arc of motion and patient satisfaction is high.

## Discussion

In old, neglected unreduced dislocations or fracture dislocations of the elbow, the procedure is almost the same, except it is more extensive.<sup>8-11</sup> The key to application of the elbow fixator is proper identification of the rotational axis of the elbow joint. Ilizarov frame is applied after completion of the arthrolysis and skin sutures are taken. The proximal unit for the humerus consists of an arch or omega ring proximally and full range distance. This distance is about 6-8 cm above the lateral epicondyle. The rings are connected to the shaft of the humerus by wires and olive wires. The distal ring is fixed to the ulna using wires. It is important to place the hinge exacting at the axis of rotation of the elbow. The Ilizarov external fixator replicates the movement of the elbow. The axis of rotation of elbow passes through the centre of the capitulum and a point just distal and anterior to the medial epicondyle. Post-operatively the movements can be started from day 2nd onwards. Total distraction of the elbow joint is 6-8 mm.

## Conclusion

If elbow is unstable after fixation of the associated fracture and repair of the lateral collateral ligament, Ilizarov hinged external fixator provides satisfactory results.

## Acknowledgments

None.

## Conflicts of interest

None.

## References

- Morrey BF, Askew LJ, Chao EYS. A biomechanical study of normal functional elbow motion. *J Bone Joint Surg.* 1981;63(6):872-877.
- Morrey BF. *The elbow: Master techniques in orthopaedic surgery.* Lippincott Williams and Wilkins, Philadelphia, USA. 1994.
- Morrey BF. *The elbow and its disorders.* (3rd edn). 2000;pp.646-654.
- Bari MM. A color atlas of limb lengthening surgical reconstruction and deformity correction by Ilizarov technique. 2013;pp.326-329.

5. Ilizarov GA. Transosseous Osteosynthesis Theoretical and clavicle aspects of the regeneration and growth of tissue springer-Verlog. 1992;Pp.420–425.
6. Hastings H, Graham TJ. The classification and treatment of heterotopic ossification about the elbow and forearm. *Hand clinic*. 1994;10:417–437.
7. Morrey BF. Post-traumatic stiffness: Distraction arthroplasty. *The elbow and its disorders*. (2nd edn), WB Saunders, Philadelphia, USA. 1993;476–491.
8. Regan WD, Reilly CD. Distraction arthroplasty of elbow. *Hand Clin*. 1993;9(4):719–728.
9. Josefson PO, Johnell O, Gentz CF. Long term sequelae of simple dislocation of the elbow. *J Bone and Joint Surg*. 1984;66(6):927–930.
10. Morrey BF. Post-traumatic contracture of the elbow, operative treatment including distraction orthoplasty. *J Bone Joint Surg*. 1990;72(4):601–618.
11. Weizenbluth M, Eichenblat M, Lipskeir E, et al. Arthrolysis of elbow: 13 cases of post-traumatic stiffness. *Acta Orthop Scand*. 1989;60(6):642–645.